

Telehealth Rheumatology Presenting Procedure

1. SCOPE

- 1.1. MCHS Telehealth Presenter
- 1.2. Facilities and departments included in the scope listed above are further defined in the [Scope Definition Resource Guide](#) if not specifically outlined above.

2. DEFINITIONS & EXPLANATIONS OF TERMS

2.1. Abbreviations

- GCA: Giant Cell Arteritis
- LPN: Licensed Practice Nurse
- MA: Medical Assistant
- MCHS: Marshfield Clinic Health System
- PMI: Point of Maximum Impulse
- RN: Registered Nurse
- ROM: Range of Motion
- RUQ: Right Upper Quadrant

2.2. Definitions

- Aortic valve: is at the second right intercostal space at the sternal border.
- Articular disease: Of or relating to a joint or joints; the articular surfaces of bones.
- Ataxia: a gait that lacks coordination with instability
- Costal Margin: lower (abdominal) border of the front of the rib cage formed by the costal cartilages of ribs 7 to 10.
- Cricoid cartilage: ring-shaped cartilage of the larynx
- Distal: situated away from the center of the body or from the point of attachment
- GCA: Causes swelling and thickening of the small temporal artery under the skin
- Homan's sign: discomfort behind the knee on forced dorsiflexion of the foot
- Hypertonia: increased tone
- Hypotonia: decreased tone
- Palpation: method of feeling with the fingers or hands during a physical examination.

- Passive range of motion: movement of the joint through range of motion with no effort from the patient
- Point of Maximal Impulse (PMI): is at the apex; fifth left intercostal space at the midclavicular line
- Proximal: situated nearer to the center of the body or the point of attachment.
- Pulmonic valve: is at the second left intercostal space at the sternal border.
- Pulsatile: throbbing
- Telepresenter: an RN, LPN or MA who is trained to use technology, such as digital stethoscope, otoscope, examination camera, etc, to facilitate comprehensive exams under provider guidance
- Tricuspid valve: is at the fifth left intercostal space at the sternal border.
- Weakness: impaired strength

Live

PROCEDURE

3. PROCEDURE BODY

Purpose Statement: All clinical staff responsible for the presenting of patients to Rheumatology Services or any provider who may need a component of a Rheumatology physical exam shall be proficient in providing neurological exam data via Telehealth technologies while working within scope of practice.


3.1. Pre-Consult Preparation

- a. See [Core Telepresenting Procedure](#)
- b. Be sure to select the appropriate provider visit and the necessary package that coincides with the visit
 - Height
 - Weight
 - Blood pressure
 - For patients with GCA, collect blood pressures on bilateral thighs and bilateral upper extremities
 - Pulse
 - Temperature
- c. Fill out Rapid 3 form and enter total score results in Dashboard
 - [Instructions for filling out Rapid 3 Form](#)
- d. Have patient fill out Pain Questionnaire under prep tab in Document Manager, if applicable

3.2. Provider Directed Physical Exam:

- a. Gait Assessment
 - Provider will instruct the patient to walk across the room or down the hall, then turn and come back observing posture, balance, the arms swinging at the sides, and turns are accomplished smoothly.
 - Provider may request patient to tandem walk (heel-to-toe) revealing an ataxia not previously observed.
- b. Oral Cavity
 - Be prepared to use the handheld camera to assist the provider to inspect the mouth for ulcers.
- c. Neck Assessment
 - Thyroid Exam:
 - With the hand held camera or room camera, assist the provider to inspect the neck for the thyroid gland.
 - Instruct the patient to tip their head back in a sniffing position.
 - Direct peripheral lighting with goose neck lamp downward from the tip of the patient's chin to allow the provider to inspect the region below

the cricoid cartilage (located just below the thyroid cartilage [Adam's apple]). The thyroid is located just below the cricoid cartilage. The lower border of the large thyroid gland will be outlined with peripheral lighting.

- With the patient's head tipped back, instruct the patient to sip some water.
 - The provider will be watching for upward movement of the thyroid gland, noting its contour and symmetry.
 - In a similar fashion, repeat the exam to examine the left lobe.
 - Report Surface (lumpy or hard), enlargement (right > left), consistency of the gland, along with any nodules or tenderness
- If the provider requests the Telehealth nurse to palpate the thyroid gland:
- Stand behind the patient and ask the patient to slightly flex the neck to relax the muscles.
 - Place the fingertips of both hands on either side of the trachea just below the cricoid cartilage.
 - With the patient's head tipped back, Instruct the patient to sip some water.
 - Feel the thyroid isthmus rise up under the finger pads. Please note it is often not palpable.
 - Displace the trachea to the right with the fingers of the left hand; with the right-hand fingers, palpate laterally for the right lobe of the thyroid in the space between the displaced trachea and the relaxed sternomastoid muscle
- 
- Find the lateral margin.
 - In a similar fashion, repeat the exam to examine the left lobe.
 - Report surface (lumpy or hard), enlargement (right > left), consistency of the gland, along with any nodules or tenderness.

d. Lung Assessment

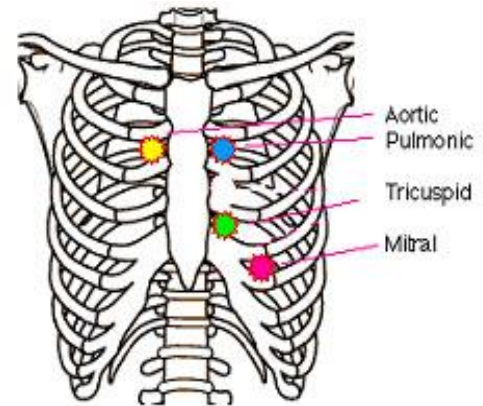
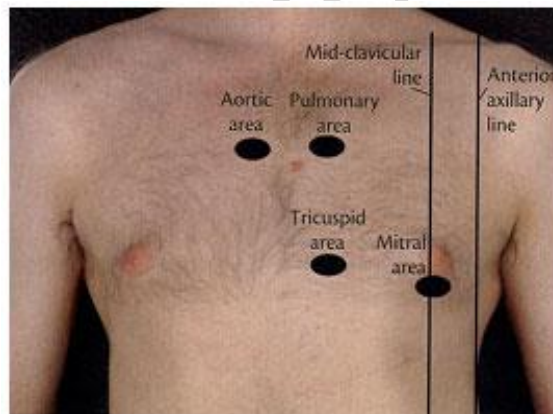
- Position patient so his or her posterior side is to the room camera
- Place limited pressure with the digital stethoscope at the six posterior lung fields for two complete breaths or until prompted by provider to switch landmarks.
- Begin with upper lobes of lung, moving the diaphragm of the stethoscope in a ladder-like pattern, from one side to the other. This will allow the

provider to identify patterns of breath sounds and compare symmetric areas of the lungs.

- Position patient with anterior side facing the room camera. Use the digital stethoscope to auscultate two anterior lung fields or until prompted by provider to switch landmarks

e. Heart assessment

- Position patient's anterior side to room camera and apply limited pressure to the digital stethoscope to auscultate in the four landmarks below.
 - Aortic valve
 - Pulmonic valve
 - Tricuspid valve
 - Mitral Valve/Point of Maximal Impulse (PMI)



- Watch the provider for cues to move to the next landmark.

f. Abdominal assessment: Be prepared to use both room camera and hand held camera for provider directed abdominal assessment

- Instruct patient to indicate if they experience any discomfort during palpation. Watch for non-verbal signs of discomfort e.g. patient pulls away, facial expressions
- May try the following measures to enhance complete muscle relaxation: Bend patient's knees, Teach person to breathe slowly, Engage patient in conversation
 - General Abdominal Palpation Technique:

Use flat part of hand or pads of fingers, not fingertips.

Fingers should be together, avoid sudden jabs.

Use light (push down 1cm) to deeper (push down 5 to 8 cm) pressure

Report any abnormal enlargement, tenderness or masses to the provider

If you feel a mass, report to provider: location, size, shape, consistency (soft, firm, hard), Surface (smooth, nodular), Mobility, pulsatile, and tenderness

- Liver Palpation Technique:

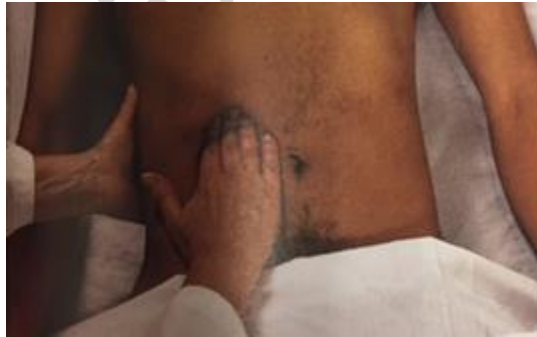Place left hand under patient's back parallel to 11th and 12th Ribs and lift up to support abdominal contents

Place Right hand on RUQ with fingers parallel to midline

Push down deeply (5cm to 8cm) under the right costal margin

Ask patient to breathe slowly

With every exhalation, move your palpating hand up 1 or 2 cm to feel for the edge of the liver



Note: You may feel a firm, regular ridge, but often times the liver is not palpable and you feel nothing firm.

g. Joint assessment/palpation

- Using room camera or handheld video camera show provider joints so provider can access for swelling and redness
- Palpate each joint, including its skin for temperature, and its muscles for bony articulation, and area of joint capsule
 - Access joints for heat, tenderness, swelling, boggy or masses
 - Compare one side to the other

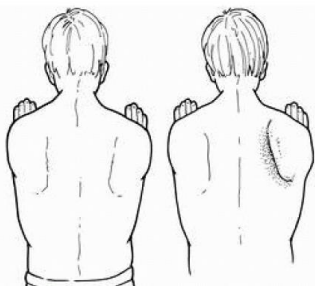
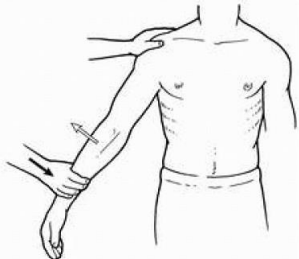

h. Range of Motion

- Ask patient for active (voluntary) ROM by modeling the movements yourself as appropriate
- If you see a limitation, gently attempt passive ROM
 - Limitation in ROM is the most sensitive sign of joint disease
 - Articular disease, as in arthritis, produces swelling and tenderness around the whole joint and it limits ROM across all planes in both active and passive motion

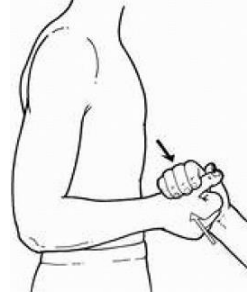
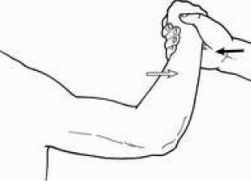

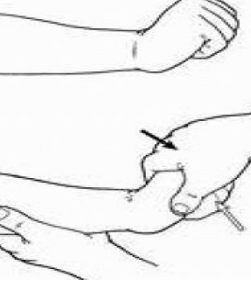
i. Muscle Tone

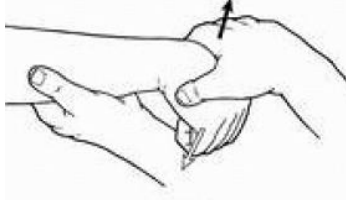
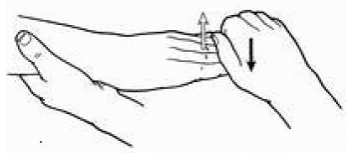
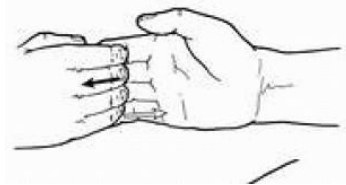
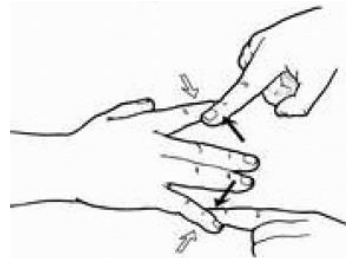

- Provider will direct Telepresenter to assess muscles and joints
 - Telepresenter puts joints through normal range of motion
 - Systematic evaluation proceeds from:
 - shoulder, elbow, wrist, and fingers in upper extremities
 - hip, knee and ankle in lower extremities
 - Compare findings from left side to right side
 - Report any findings or variations in muscle tone to provider (e.g. Normal, hypertonia or hypotonia)
- j. Muscle Strength: Not all muscles may be assessed individually, but major groups are assessed; more detailed examination may be conducted if deficits are noted in a particular area
- Muscle Strength Grading:
 - Grade 5 Full ROM against gravity, full resistance
 - Grade 4 Full ROM against gravity, some resistance
 - Grade 3 Full ROM with gravity
 - Grade 2 Full ROM with gravity eliminated (passive motion)
 - Grade 1 Slight Contraction
 - Grade 0 No Contraction
 - Compare functional level of each muscle/muscle group to functional level of same muscle/muscle group on opposite side (e.g. compare muscle strength of Right Bicep to Left Bicep)
 - Pattern of muscle extremity evaluation includes both proximal and distal muscle groups
 - Provider instructs patient to move muscles actively against gravity and then against resistance provided by Telepresenter.
 - Provider decides muscles/muscle groups to be assessed and directs Telepresenter through assessment of muscle strength.
 - Make your directions to patient clear. Demonstrate movements as necessary.
 - See table below for muscle assessment details
 - Upper Extremity
 - Deltoid C 5, 6
 - Biceps C 5, 6
 - Triceps C 6, 7, 8
 - Wrist flex/extend C7, 8
 - Grip C7, 8, T1
 - Interossei (keeping fingers spread apart) C 8, T 1

- Lower Extremity
 - Iliopsoas L 1, 2, 3
 - Hip adductors L-2, L-3, L-4
 - Quadriceps L 2, 3, 4
 - Anterior Tibialis L 4, 5
 - Gastrocnemius S 1, 2
 - EHL (Big toe extension) L 5


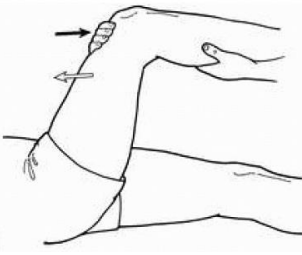

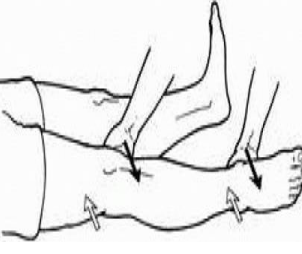
Muscle Group/ Muscle/ Spinal Level	Patient Instructions	Examiner and Observation	Image Dark Arrow = Provider action Light Arrow = Patient action
Shoulder Serratus Anterior C 5, 6, 7	Patient pushes against a wall with arms extended horizontally in front of them. Extend your arms parallel to floor and push with your palms against wall.	Observe scapula for increased prominence of scapular tip (winging). Normally, each scapula is close to thorax. Winging suggests serratus anterior muscle weakness.	
Shoulder Deltoid C 5, 6	Instruct patient to flex elbow slightly and move upper arm away from their body. (Alternative, ask patient to position his or her arms like chicken wings.)	Try to push abducted upper arms down against resistance. Patient attempts to abduct his arm against resistance. Deltoid contraction can be seen and palpated.	
Upper Arm Biceps C 5, 6	Flex your elbow and make a muscle with your palm parallel to shoulder.	Try to pull flexed forearm open. On attempts to flex forearm against resistance, bicep muscle contraction can be seen and palpated.	

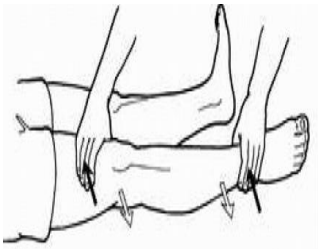

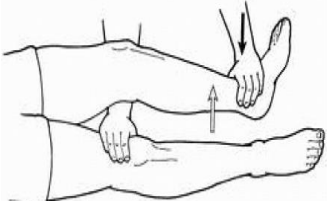
PROCEDURE


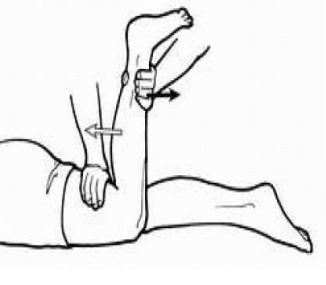


Muscle Group/ Muscle/ Spinal Level	Patient Instructions	Examiner and Observation	Image Dark Arrow = Provider action Light Arrow = Patient action
Upper Arm Brachioradialis C5, 6	Flex your elbow and make a muscle while your palm is pointed at midline	Try to pull flexed forearm open. On flexion at semi pronated forearm (thumb up) against resistance, muscle contraction can be seen and palpated.	
Upper Arm Triceps C6, 7, 8	Push me away with that same arm.	Provide resistance, thus trying to prevent extension. On attempts to extend partially flexed forearm against resistance, of triceps contraction can be seen and palpated.	
Pronator Drift	Outstretch both arms in front of you parallel to floor with hands open and palms up. Fully extend elbows and wrists also. Now close your eyes and stay that way for 20 or 30 seconds.	(May examine patient while standing or sitting.) Observe for slow pronation of wrist, slight flexion of elbow and fingers, and a downward and lateral drift of hand; called pronator drift. Suggests mild hemiparesis and may be noted before any significant weakness noted.	
Lower Arm Wrist Extension C7, 8	Extend your wrist and don't let me straighten it.	Examiner attempts to straighten wrist. If straightened, it suggests wrist drop. On attempts to extend hand at wrist against resistance, bellies of extensors carpi radialis longus, carpi ulnaris, and digitorum communis can be seen and palpated	

Muscle Group/ Muscle/ Spinal Level	Patient Instructions	Examiner and Observation	Image Dark Arrow = Provider action Light Arrow = Patient action
Lower Arm Wrist Flexion C7, 8	Flex your wrist and don't let me straighten it.	Examiner attempts to straighten wrist.	
Hand and Fingers Grip C7, 8, T1 Extension of fingers	Put your fingers straight out and don't let me push them down.	Try to push fingers down.	
Hand and Fingers Grip C7, 8, T1 Flexion of Fingers	Flex your fingers and don't let me straighten them.	Try to straighten fingers.	
Hand and Fingers Interossei C8, T1 Adduction of fingers	Put your hand on table with fingers slightly spread. Try to resist my attempt to pull your fingers outward.	Try to pull fingers outward.	
Hand and Fingers Interossei C8, T1 Abduction of fingers	Put your hand on table and spread your fingers. Try to resist my attempt to bring fingers together.	Try to push fingers together.	

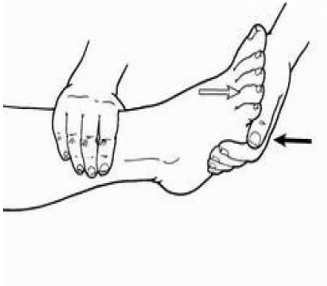

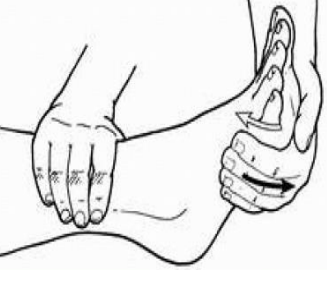
PROCEDURE

Muscle Group/ Muscle/ Spinal Level	Patient Instructions	Examiner and Observation	Image Dark Arrow = Provider action Light Arrow = Patient action
Hand and Fingers Grip C7, 8, T1 Opposition of thumb	Touch tip of your little finger with your thumb. (thumbnail should be parallel to palm.)	Try to pull thumb away from little finger with your index finger or thumb.	
Hip Iliopsoas L1, 2, 3 Hip Flexion	Flex your thigh against resistance provided (try to pull/bring knee towards head against my resistance)	Position patient supine. patient attempts to flex thigh against resistance	
Hip Iliopsoas L 1, 2, 3 Hip Flexion	Raise knee off table against my resistance.	Alternate method: patient sits on edge of exam table or chair with legs dangling. Stabilize pelvis by placing your hand over iliac crest and other hand over distal femoral portion of knee; apply resistance as patient attempts to raise knee off table	
Hip Hip adductors L2, L3, L4 Hip Adduction	Lie on your back: extend your legs; now separate them about 6 inches, (examiner places both hands firmly between both knees). Try to bring your knees together	Place both hands firmly between both knees, recumbent patient attempts to adduct (move inward) extended leg against resistance; contraction of adductor muscles can be seen and palpated. Determine how much resistance patient can overcome.	


Muscle Group/ Muscle/ Spinal Level	Patient Instructions	Examiner and Observation	Image Dark Arrow = Provider action Light Arrow = Patient action
Hip Hip abductors, Gluteus Medius and Minimus L2, L3, L4 Hip Abduction	Lie on your back: Spread both legs against my hands. Try keeping me from bring your legs together	After legs are abducted, (examiner places both hands on lateral thighs just above patient's knees.) Recumbent patient attempts to move extended leg outward against resistance; contraction of gluteus medius and tensor fasciae latae can be palpated. Determine how much resistance patient can overcome.	 <p>The diagram shows a patient lying on their back with legs abducted. The examiner's hands are placed on the lateral thighs just above the knees. A dark arrow points downwards from the examiner's hands, indicating resistance. A light arrow points outwards from the patient's legs, indicating the patient's action of moving the leg outward.</p>
Hip Gluteus Maximus L5, S1, S2 Hip Extension	Instruct patient try and keep thigh from touching bed	Examiner's hand is positioned on posterior thigh and other on top; feel for muscle contraction on posterior thigh. Attempt to push leg down to bed Alternate method: ask Patient to stand from a sitting position without using arms.	 <p>The diagram shows a patient sitting on a bed with one leg extended. The examiner's hands are positioned on the posterior thigh and the top of the thigh. A dark arrow points downwards from the examiner's hands, indicating resistance. A light arrow points upwards from the patient's leg, indicating the patient's action of pushing the leg down.</p>
Upper Leg Quadriceps L2, 3, 4 Knee Extension	Straighten your lower leg.	Patient prone, Stabilize thigh by placing one hand just above knee. Place other hand just above ankle and provide resistance. quadriceps for a contraction with stabilizing hand.	 <p>The diagram shows a patient lying prone with one leg extended. The examiner's hands are positioned on the thigh just above the knee and the lower leg just above the ankle. A dark arrow points upwards from the examiner's hands, indicating resistance. A light arrow points downwards from the patient's leg, indicating the patient's action of straightening the leg.</p>

Muscle Group/ Muscle/ Spinal Level	Patient Instructions	Examiner and Observation	Image Dark Arrow = Provider action Light Arrow = Patient action
Upper Leg Quadriceps L2, 3, 4 Knee Extension	Straighten your lower leg.	Alternate method: sitting on side of examining table: direct patient to extend knee	
Upper Leg Hamstrings L5, S1, S2 Knee flexion	Flex your knee. Bring foot towards head	Examiner grasps partially flexed knee about 4 inches above ankle and stabilizes hip with other hand; provides resistance against flexion.)	
Upper Leg Hamstrings L5, S1, S2 Knee flexion	Ask patient to bend knee and keep it bent while you provide resistance.	Alternate methods: have patient sit on edge of examining table with legs dangling. Ask patient to bend knee and keep it bent while you provide resistance or ask patient to squat in a deep knee bend (should be able to flex both knees symmetrically).	
Lower Leg and Ankle Anterior Tibialis L4, 5 Ankle Dorsiflexion	Examiner positions ankle in neutral position and then places other hand on top of foot near fifth metatarsal. Pull your toes toward your nose.	Anchor ankle by stabilizing heel; with your flattened fingers on top of foot, provide resistance to dorsiflexion. Patient attempts to dorsiflex foot against resistance; contraction of tibialis anterior can be seen and palpated Alternate method: ask patient to walk on heels.	

PROCEDURE

Muscle Group/ Muscle/ Spinal Level	Patient Instructions	Examiner and Observation	Image Dark Arrow = Provider action Light Arrow = Patient action
<p>Lower Leg and Ankle</p> <p>Gastrocnemius S1, 2</p> <p>Plantarflexion of ankle</p>	<p>Press down like on gas pedal.</p>	<p>Anchor ankle by stabilizing heel; with your palm on bottom of foot, provide resistance to plantarflexion. Patient attempts to plantar flex foot at ankle joint against resistance; Contraction of gastrocnemius and associated muscles can be seen and palpated</p> <p>Alternative method: ask patient to walk on toes.</p>	 <p>The diagram shows a lateral view of a right foot and ankle. The examiner's left hand is placed on the heel to stabilize it. The right hand is placed on the bottom of the foot, with a dark arrow pointing downwards, indicating resistance to plantarflexion. A light arrow points upwards from the ball of the foot, indicating the patient's action of plantarflexion.</p>
<p>Ankle and Foot</p> <p>Foot inversion L4, 5</p>	<p>Try to move your foot outward and down.</p>	<p>Position thumb to dorsiflex and invert foot. Patient attempts to raise inner border of foot against resistance; tendon of tibialis posterior can be seen and palpated just behind medial malleolus Try to force foot into plantarflexion and eversion by pushing against head and shaft of first metatarsal; tendon of tibialis posterior can be seen and palpated behind medial malleolus.</p>	 <p>The diagram shows a lateral view of a right foot and ankle. The examiner's left hand is placed on the medial malleolus to stabilize the ankle. The right hand is placed on the first metatarsal, with a dark arrow pointing towards the foot, indicating resistance to inversion. A light arrow points upwards from the inner border of the foot, indicating the patient's action of inversion.</p>
<p>Ankle and Foot</p> <p>Foot eversion S1 J</p>	<p>Turn your foot outward.</p>	<p>Secure ankle by stabilizing heel and place your other hand that forces plantarflexion and eversion. Provide resistance to eversion by pushing on fifth metatarsal with palm. Patient attempts to raise outer border of foot against resistance; tendons</p>	 <p>The diagram shows a lateral view of a right foot and ankle. The examiner's left hand is placed on the heel to stabilize it. The right hand is placed on the fifth metatarsal, with a dark arrow pointing towards the foot, indicating resistance to eversion. A light arrow points upwards from the outer border of the foot, indicating the patient's action of eversion.</p>

PROCEDURE

Muscle Group/ Muscle/ Spinal Level	Patient Instructions	Examiner and Observation	Image Dark Arrow = Provider action Light Arrow = Patient action
		of peronei longus and brevis can be seen and palpated just above and behind lateral malleolus. Alternative method: patient walks on medial borders of feet.	
Toe Extensor Halucis Longus (EHL) muscle L5 Big toe extension	Ask patient to move large toe against resistance up towards their face.	Apply downward resistance on big toe while patients tried to pull toe up towards face. This tests extensor halucis longus muscle.	

k. Sensation

- Provider determines patient's ability to perceive various types of sensations.
- Compare left and right sides of body as well as sensory perceptions at distal and proximal portions of all extremities. Testing proceeds in an orderly fashion.
- Body areas commonly evaluated include face, neck, deltoid regions, forearm, hands (top side), chest, abdomen, thighs, lower legs, and feet (top surface).
- Sensory function is rated according to following scale:
 - 2: normal
 - 1: present, but diminished (abnormal)
 - 0: absent
- Sensation Assessment
 - Provider determines areas to be assessed and directs telepresenter assessment. Following areas may/may not be assessed:
 - posterior aspect of the shoulders (C4)
 - lateral aspect of the upper arms (C5)
 - medial aspect of the lower arms (T1)
 - tip of the thumb (C6)
 - tip of the middle finger (C7)

tip of the pinky finger (C8)

thorax, nipple level (T5)

thorax, umbilical level (T10)

upper part of the upper leg (L2)

lower-medial part of the upper leg (L3)

medial lower leg (L4)

lateral lower leg (L5)

sole of foot (S1)

- Instruct patient to close eyes
- Instruct patient to tell provider if they notice a difference in strength of sensation on each side of their body
- Touch one body part followed by corresponding body part on other side (e.g., right shoulder then left shoulder) with same instrument. This allows patient to compare sensations and note asymmetry.
- Light touch

A wisp of cotton, alcohol wipe, gauze, brush etc. is used to lightly touch various areas of skin.

Patient tells provider/you if they can feel light touch in area being assessed.

I. Deep Tendon Reflexes:

- Refer to [Reflex Guide](#)
- Encourage patient to relax.
- Position limbs properly and symmetrically. Hold reflex hammer loosely between your thumb and index finger so that it swings freely in an arc within limits set by your palm and other fingers.
- With wrist relaxed, strike tendon briskly using a rapid wrist movement. Reflex response depends partly on the force of your stimulus. Compare response of one side with other.
- Clinician will grade reflexes based on following scale:
 - 4+= Very brisk, hyperactive with clonus (spasmodic alternation of muscular contraction and relaxation).
 - 3+= Brisker than average; possibly but not necessarily indicative of disease.
 - 2+= Average; normal
 - 1+= Somewhat diminished; low normal
 - 0= No response/ absent.

Radial

Biceps

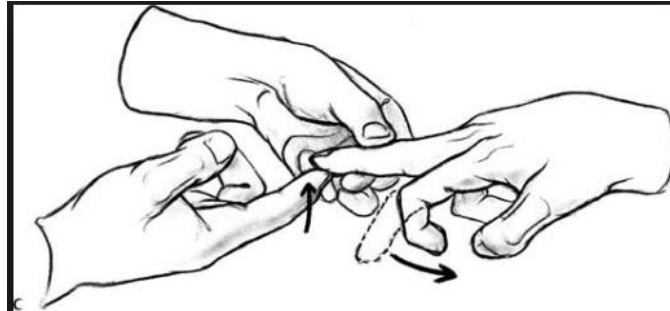PROCEDURE

Triceps

Knee

Ankle

Hoffmann's Sign: Tap or flick the nail of the middle finger to produce flexion of the index finger to the thumb



3.2. Post Physical Exam

a. See [Telehealth Core Presenting Procedure](#)

3.3. Post Consult Considerations

a. See [Telehealth Core Presenting Procedure](#)

PROCEDURE

4. ADDITIONAL RESOURCES

4.1. References:

- Jarvis 7th Edition
- <http://medical-dictionary.thefreedictionary.com/>
- <https://www.rheumatology.org/I-Am-A/Patient-Caregiver/Diseases-Conditions/Giant-Cell-Arteritis>. Retrieved 2/21/18

5. DOCUMENT HISTORY

Version No.	Revision Description
1.0	New Document
2.0	See Version History
3.0	Administrative Override: Removed Marshfield Clinic Logo, Updated Quick Part in Header, Reformat of Section 2. Updated scope statement with include MCHS, Reformat of Section 2. No Content Changes.
4.0	Removed hyperlink from 3.1b under blood pressure, Updated 3.1d.

6. DOCUMENT PROPERTIES

Primary Author: Elsen, Julianne M

Co-Author(s):

Approver(s): This document has been electronically signed and approved by: Castellano, James B on: 10/19/2020 9:47:20 AM

This document has been electronically signed and approved by: Simon, Tammy A. on: 10/19/2020 11:30:58 AM

This document has been electronically signed and approved by: Krueger, Kori K MD on: 10/27/2020 9:51:12 AM

Live

PROCEDURE