

Telehealth Physical Medicine Presenting Procedure

1. SCOPE

- 1.1. MCHS Telepresenters
- 1.2. Facilities and departments included in the scope listed above are further defined in the [Scope Definition Resource Guide](#) if not specifically outlined above.

2. DEFINITIONS & EXPLANATIONS OF TERMS

2.1. Abbreviations

- EHR: Electronic Health Record
- LPN: Licensed Practical Nurse
- MA: Medical Assistant
- MCHS: Marshfield Clinic Health System
- RN: Registered Nurse

2.2. Definitions

- Adjusted age: A baby's age based on his/her due date. Healthcare providers may use this age when evaluating the baby's growth and development. So if a baby is 6 months old but was born two months early, his adjusted age is 4 months
- Cyanotic: Showing cyanosis (bluish discoloration of the skin and mucous membranes due to not enough oxygen in the blood)
- Hypertonia: Increased tightness of muscle tone and reduced capacity of the muscle to stretch caused by damage to the motor nerve pathways in the central nervous system
- Hypotonia: Decreased muscle tone and strength that results in floppiness.
- Neurocutaneous: of, relating to, or affecting the skin and nerves
- Muscle Strength Grading:
 - ◇ 5 = Active movement against gravity and full resistance; normal muscle strength
 - ◇ 4 = Active movement against gravity and some resistance; examiner can overcome muscle resistance
 - A plus [+] or a minus [-] in "4" category may be used to indicate how strong patient's muscle strength was against examiner's resistance. A "4+" indicates a large amount of resistance by examiner was necessary for patient's muscle to be finally overcome
 - ◇ 3 = Active movement against gravity
 - ◇ 2 = Active movement of body part when gravity is eliminated

◇ 1 = A very weak muscle contraction is palpated; only a trace of a contraction is evident, but no active movement of body part is noted

◇ 0 = No muscle contraction is detectable

- Muscular atrophy: refers to a loss of muscle bulk (wasting) and results from diseases of the peripheral nervous system such as diabetic neuropathy, as well as diseases of the muscles.
- Parachute sign (also known as startle reflex): a primitive reflex response observed in the normal newborn but typically suppressed by 3-4 months of age. Any sudden stimulus (for example, being dropped 5-10 cm through space) causes flexion of the hip and knee joints with fanning of the fingers followed by fist clenching and extension of the upper limbs followed by flexion.
- Reflexes –
 - Biceps Tendon- located in the front of the bend of the elbow; located in the right antecubital fossa. The biceps reflex is elicited by placing your thumb on the biceps tendon and striking your thumb with the reflex hammer and observing the arm movement
 - Triceps Tendon: located just above the elbow bend (funny bone), the triceps reflex is measured by striking the triceps tendon directly with the hammer while holding the patient's arm with your other hand.
 - Brachioradialis: located along the thumb side of the wrist, about 2-3 inches above the round bone at the bend of the wrist. The brachioradialis reflex is observed by striking the brachioradialis tendon directly with the hammer when the patient's arm is resting. Strike the tendon roughly 2-3 inches above the wrist. This normally causes contraction of the brachioradialis and hence flexion of the elbow.
 - Patellar/Quadriceps Reflex: A reflex contraction of the quadriceps muscle resulting in a sudden involuntary extension of the leg, produced by a sharp tap to the tendon below the patella.
 - Achilles Reflex: A reflex bending of the foot resulting from contraction of the calf muscles when the Achilles tendon is sharply struck.
 - Babinski: a reflex extension of the great toe with flexion of the other toes, evoked by stroking the sole of the foot: normal in infants but otherwise denoting central nervous system damage.
 - Ankle Clonus: a reflex elicited by quick vigorous dorsiflexion of the foot while the knee is held in a flexed position resulting in repeated clonic movement of the foot as long as it is maintained in dorsiflexion. Feel for oscillations between flexion and extension of the foot indicating clonus
 - Hoffman's Sign: elicited by holding the patient's middle finger between the examiner's thumb and index finger. Ask the patient to relax their fingers completely. Once the patient is relaxed, using your thumbnail press down on the patient's fingernail and move downward until your nail "clicks" over the end of the patient's nail. Normally, nothing occurs. A positive Hoffman's response is when the other fingers flex transiently after the "click".

- Rigidity: Increased tone resistance to passive movement throughout movement; due to steady contraction of flexors and extensors
- Spasticity: Resistance to passive movement for portions of the movement; due to loss of suprasegmental influence on the tonic contractions of the muscle; usually greatest in the flexors of the upper extremity and the extensors of the lower extremity.
- Telepresenter: An RN, LPN or MA who is trained to use technology, such as digital stethoscope, otoscope, examination camera, etc, to facilitate comprehensive exams under provider guidance
- Weakness: is impaired strength.

Live

PROCEDURE

3. PROCEDURE BODY

Purpose Statement: All clinical staff responsible for the presenting of patients to Physical Medicine Services or any provider who may need a component of physical exam, shall be proficient in providing physical medicine exam data via Telehealth technologies while working within scope of practice

3.1. Pre-Consult Preparation

a. See [Telehealth Core Presenting Document](#)

- Vital signs: Be sure to select the appropriate provider and the necessary package that coincides with the visit
- NICU Follow up vital signs
 - Weight using baby scale
 - Length
 - Head Circumference measured in cm
- Physical Medicine and Rehab Follow up vital signs
 - Height, if patient is able
 - Weight
 - Blood pressure
 - Pulse
 - Temperature
 - Pain level in concerned body area from 0-10 on day of visit

3.2. Pre-assessment

- a. Physical Medicine Medical Assistant will take patient history and document in EHR in provider's document for visit

3.3. Provider Directed Physical Exam: Under direction of the provider, the Telepresenter will assist with following physical exam while ensuring that patient is always framed appropriately so provider can see all aspects of exam

a. Head and Neck assessment

- Inspect neck for muscle: symmetry, tone, size and contour. Report abnormal findings to provider
- Using handheld camera, show provider patient's mouth so provider can access mucous membranes

b. Skin assessment

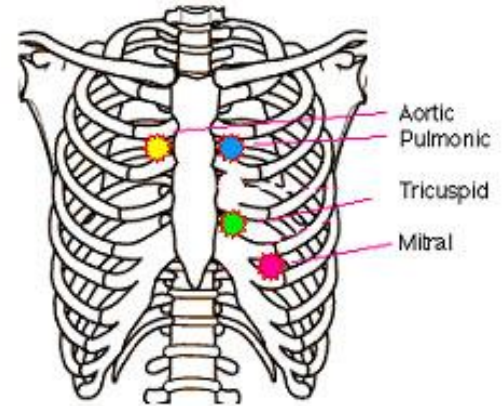
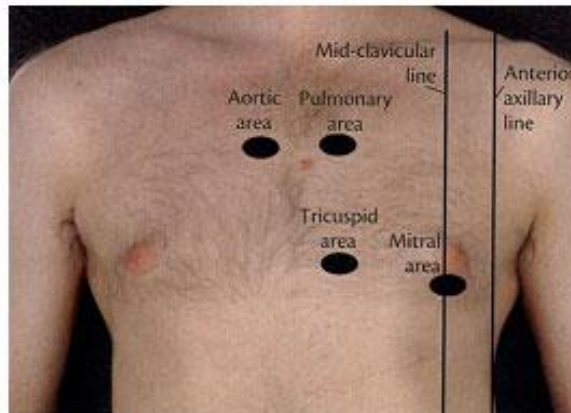
- Use room camera or handheld camera so provider can visualize the skin for bruise, abrasions, neurocutaneous signs, or other skin abnormalities.
- Injection site assessment if patient had a recent spinal injection

c. Cardiovascular assessment

- Provider will assess perfusion of patient's hands and feet
 - Are feet cyanotic?
 - Is there swelling in ankles or hands?

d. Heart

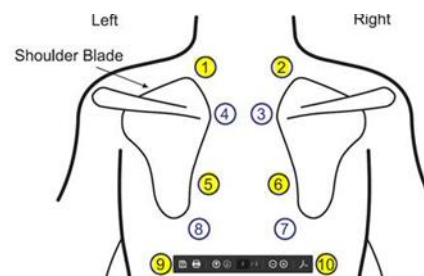
- With the patient's anterior side to the room camera, apply limited pressure to the digital stethoscope to auscultate. S3 is most important



- Aortic valve
- Pulmonic valve
- Tricuspid valve
- Point of Maximal Impulse (PMI)
- Watch the provider for cues to move to the next landmark.

e. Lungs

- Position patient so the posterior side is to the room camera. If patient is not positioned so the provider can see placement of stethoscope, must verbally state location
- Place limited pressure with the digital stethoscope at the six posterior lung fields for two complete inspirations and expirations. Watch the provider for cues to move to the next landmark
- Begin with upper lobes of lung, moving the diaphragm of the stethoscope in a ladder-like pattern, from one side to the other. This will allow the provider to identify patterns of breath sounds and compare symmetric areas of the lungs



- If provider requests anterior lung fields, position patient with anterior side facing the room camera. Use the digital stethoscope to auscultate two anterior lung fields

f. Gait Assessment

- Provider will instruct the patient to walk across the room or down the hall, then turn and come back observing posture, balance, the arms swinging at the sides, and turns are accomplished smoothly.
- Provider may request patient to tandem walk (heel-to-toe) revealing an ataxia not previously observed

g. Motor Exam

- Motor System- As the provider assesses the motor system, he/she will focus on body position, involuntary movements, characteristics of the muscles (bulk, tone, and strength), and coordination. With the hand held camera or room camera zoom in on neuromuscular activity, proceed from neck, to upper limbs, to trunk, and, finally, to lower extremities.
- Limb evaluation proceeds from proximal to distal.
 - Not all muscles may be assessed individually, but major groups are assessed; more detailed examination may be conducted if deficits are noted in a particular area
- Involuntary Movements- provider will assess for involuntary movements such as tremors or tics, noting location, quality, rate, rhythm, and amplitude. Be prepared to use camera and/or hand held camera to zoom in on action of finite motor responses or pan out for room view to show entire patient movement.
- Body position: Provider will observe patient's body position during movement and at rest.
- Muscle bulk: Provider compares size and contours of muscles, assessing if the muscles look flat or concave. Provider may pay particular attention to hands, shoulder, and thighs when assessing for atrophy.
 - Provider will inspect muscles bilaterally note:
 - symmetry
 - size
 - contour
 - muscle wasting, atrophy, or hypertrophy

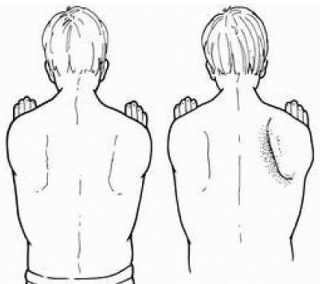
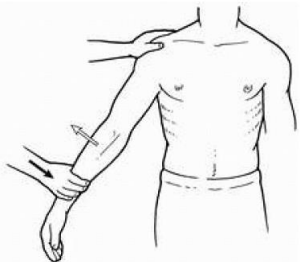
A tape measure can be used to measure a muscle and compare it with same muscle on opposite side of body. Measurements must be taken from same reference point for accuracy.

h. Muscle Tone


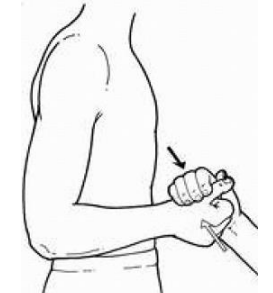
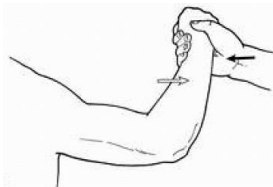

- Feel the patient's muscle resistance to passive stretch.
 - Instruct/persuade patient to relax.

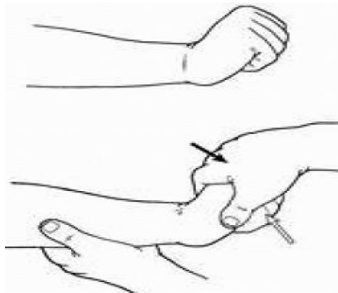

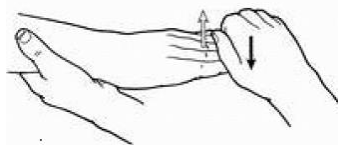
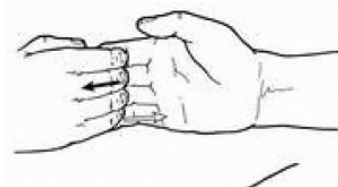

- Provider to direct Telepresenter to assess muscles and joints
 - Telepresenter puts joints through normal range of motion movements (e.g., flexion and extension).
 - Systematic evaluation proceeds from:
 - shoulder, elbow, wrist, and fingers in upper extremities
 - hip, knee, and ankle in lower extremities.
 - Compare findings from left side and right side.
 - Report/note findings or variations in muscle tone to provider (e.g. normal, hypertonia or hypotonia)
- i. Low Back Range of Motion
 - Have the patient bend forward at the waist
 - Have the patient extend backwards at the waist
 - Then have the patient twist side to side
- j. Muscle Strength
 - Muscle Strength Grading:
 - Grade 5 Full ROM against gravity, full resistance
 - Grade 4 Full ROM against gravity, some resistance
 - Grade 3 Full ROM with gravity
 - Grade 2 Full ROM with gravity eliminated (passive motion)
 - Grade 1 Slight Contraction
 - Grade 0 No Contraction
 - Compare functional level of each muscle/muscle group to functional level of same muscle/muscle group on opposite side (e.g. compare muscle strength of Right Bicep to Left Bicep)
 - Pattern of muscle extremity evaluation includes both proximal and distal muscle groups
 - Provider instructs patient to move muscles actively against gravity and then against resistance provided by Telepresenter.
 - Provider decides muscles/muscle groups to be assessed and directs Telepresenter through assessment of muscle strength.
 - Make your directions to patient clear. Demonstrate movements as necessary.
 - See table below for muscle assessment details
 - Upper Extremity
 - Deltoid C 5, 6
 - Biceps C 5, 6
 - Triceps C 6, 7, 8

- Wrist flex/extend C7, 8
- Grip C7, 8, T1
- Interossei (keeping fingers spread apart) C 8, T 1
- Lower Extremity
 - Iliopsoas L 1, 2, 3
 - Hip adductors L-2, L-3, L-4
 - Quadriceps L 2, 3, 4
 - Anterior Tibialis L 4, 5
 - Gastrocnemius S 1, 2
 - EHL (Big toe extension) L 5



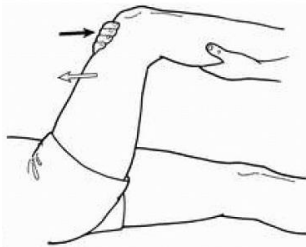


Muscle Group/ Muscle/ Spinal Level	Patient Instructions	Examiner and Observation	Image Dark Arrow = Provider action Light Arrow = Patient action
Shoulder Serratus Anterior C 5, 6, 7	Patient pushes against a wall with arms extended horizontally in front of them. Extend your arms parallel to floor and push with your palms against wall.	Observe scapula for increased prominence of scapular tip (winging). Normally, each scapula is close to thorax. Winging suggests serratus anterior muscle weakness.	
Shoulder Deltoid C 5, 6	Instruct patient to flex elbow slightly and move upper arm away from their body. (Alternative, ask patient to position his or her arms like chicken wings.)	Try to push abducted upper arms down against resistance. Patient attempts to abduct his arm against resistance. Deltoid contraction can be seen and palpated.	

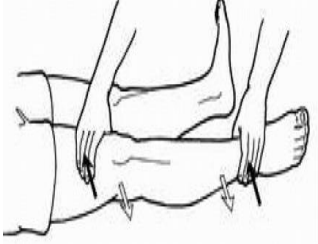
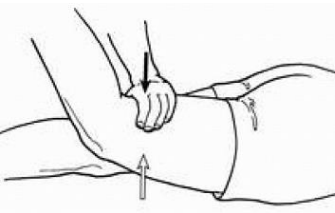
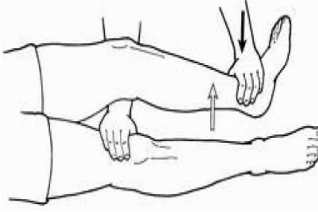
PROCEDURE





Muscle Group/ Muscle/ Spinal Level	Patient Instructions	Examiner and Observation	Image Dark Arrow = Provider action Light Arrow = Patient action
Upper Arm Biceps C 5, 6	Flex your elbow and make a muscle with your palm parallel to shoulder.	Try to pull flexed forearm open. On attempts to flex forearm against resistance, bicep muscle contraction can be seen and palpated	 A line drawing of a person's upper arm and shoulder. The arm is flexed at the elbow with the palm facing the shoulder. A dark arrow points to the biceps muscle, and a light arrow points to the forearm, indicating the patient's action.
Upper Arm Brachioradialis C5, 6	Flex your elbow and make a muscle while your palm is pointed at midline	Try to pull flexed forearm open. On flexion at semi pronated forearm (thumb up) against resistance, muscle contraction can be seen and palpated.	 A line drawing of a person's upper arm and shoulder. The arm is flexed at the elbow with the palm facing up (supinated). A dark arrow points to the brachioradialis muscle, and a light arrow points to the forearm, indicating the patient's action.
Upper Arm Triceps C6, 7, 8	Push me away with that same arm.	Provide resistance, thus trying to prevent extension. On attempts to extend partially flexed forearm against resistance, of triceps contraction can be seen and palpated.	 A line drawing of a person's upper arm and shoulder. The arm is partially flexed at the elbow. A dark arrow points to the triceps muscle, and a light arrow points to the forearm, indicating the patient's action.
Pronator Drift	Outstretch both arms in front of you parallel to floor with hands open and palms up. Fully extend elbows and wrists also. Now close your eyes and stay that way for 20 or 30 seconds.	(May examine patient while standing or sitting.) Observe for slow pronation of wrist, slight flexion of elbow and fingers, and a downward and lateral drift of hand; called pronator drift. Suggests mild hemiparesis and may be noted before any significant weakness noted.	 A line drawing of a person's upper body from the chest up. Both arms are extended forward with palms up. A dark arrow points to the right hand, and a light arrow points to the left hand, indicating the patient's action.

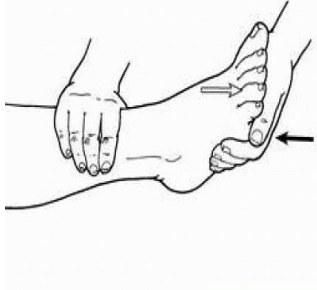
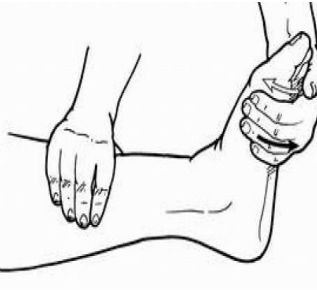
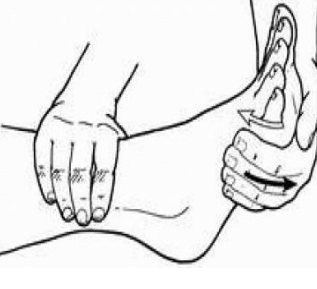
Muscle Group/ Muscle/ Spinal Level	Patient Instructions	Examiner and Observation	Image Dark Arrow = Provider action Light Arrow = Patient action
<p>Lower Arm Wrist Extension C7, 8</p>	<p>Extend your wrist and don't let me straighten it.</p>	<p>Examiner attempts to straighten wrist. If straightened, it suggests wrist drop. On attempts to extend hand at wrist against resistance, bellies of extensors carpi radialis longus, carpi ulnaris, and digitorum communis can be seen and palpated</p>	
<p>Lower Arm Wrist Flexion C7, 8</p>	<p>Flex your wrist and don't let me straighten it.</p>	<p>Examiner attempts to straighten wrist.</p>	
<p>Hand and Fingers Grip C7, 8, T1 Extension of fingers</p>	<p>Put your fingers straight out and don't let me push them down.</p>	<p>Try to push fingers down.</p>	
<p>Hand and Fingers Grip C7, 8, T1 Flexion of Fingers</p>	<p>Flex your fingers and don't let me straighten them.</p>	<p>Try to straighten fingers.</p>	
<p>Hand and Fingers Interossei C8, T1 Adduction of fingers</p>	<p>Put your hand on table with fingers slightly spread. Try to resist my attempt to pull your fingers outward.</p>	<p>Try to pull fingers outward.</p>	

PROCEDURE


Muscle Group/ Muscle/ Spinal Level	Patient Instructions	Examiner and Observation	Image Dark Arrow = Provider action Light Arrow = Patient action
Hand and Fingers Interossei C8, T1 Abduction of fingers	Put your hand on table and spread your fingers. Try to resist my attempt to bring fingers together.	Try to push fingers together.	
Hand and Fingers Grip C7, 8, T1 Opposition of thumb	Touch tip of your little finger with your thumb. (thumb nail should be parallel to palm.)	Try to pull thumb away from little finger with your index finger or thumb.	
Hip Iliopsoas L1, 2, 3 Hip Flexion	Flex your thigh against resistance provided (try to pull/bring knee towards head against my resistance)	Position patient supine. patient attempts to flex thigh against resistance	
Hip Iliopsoas L 1, 2, 3 Hip Flexion	Raise knee off table against my resistance.	Alternate method: patient sits on edge of exam table or chair with legs dangling. Stabilize pelvis by placing your hand over iliac crest and other hand over distal femoral portion of knee; apply resistance as patient attempts to raise knee off table	
Hip Hip adductors L2, L3, L4 Hip Adduction	Lie on your back: extend your legs; now separate them about 6 inches, (examiner places both hands firmly between both	Place both hands firmly between both knees, recumbent patient attempts to adduct (move inward) extended leg against resistance; contraction of adductor muscles can be seen and palpated.	

Muscle Group/ Muscle/ Spinal Level	Patient Instructions	Examiner and Observation	Image Dark Arrow = Provider action Light Arrow = Patient action
	knees). Try to bring your knees together	Determine how much resistance patient can overcome.	
Hip Hip abductors, Gluteus Medius and Minimus L2, L3, L4 Hip Abduction	Lie on your back: Spread both legs against my hands. Try keeping me from bring your legs together	After legs are abducted, (examiner places both hands on lateral thighs just above patient's knees.) Recumbent patient attempts to move extended leg outward against resistance; contraction of gluteus medius and tensor fasciae latae can be palpated. Determine how much resistance patient can overcome.	 <p>A line drawing of a person lying on their back. The examiner's hands are placed on the lateral thighs, just above the knees. A dark arrow points downwards from the examiner's hands, indicating resistance. A light arrow points outwards from the patient's legs, indicating the direction of movement.</p>
Hip Gluteus Maximus L5, S1, S2 Hip Extension	Instruct patient try and keep thigh from touching bed	<p>Examiner's hand is positioned on posterior thigh and other on top; feel for muscle contraction on posterior thigh. Attempt to push leg down to bed</p> <p>Alternate method: ask Patient to stand from a sitting position without using arms.</p>	 <p>A line drawing of a person sitting on a bed. The examiner's hands are positioned on the posterior thigh and the top of the leg. A dark arrow points downwards from the examiner's hands, indicating resistance. A light arrow points upwards from the patient's leg, indicating the direction of movement.</p>
Upper Leg Quadriceps L2, 3, 4 Knee Extension	Straighten your lower leg.	Patient prone, Stabilize thigh by placing one hand just above knee. Place other hand just above ankle and provide resistance. quadriceps for a contraction with stabilizing hand.	 <p>A line drawing of a person lying prone. The examiner's hands are positioned on the thigh (just above the knee) and the ankle. A dark arrow points downwards from the examiner's hands, indicating resistance. A light arrow points upwards from the patient's leg, indicating the direction of movement.</p>

Muscle Group/ Muscle/ Spinal Level	Patient Instructions	Examiner and Observation	Image Dark Arrow = Provider action Light Arrow = Patient action
Upper Leg Quadriceps L2, 3, 4 Knee Extension	Straighten your lower leg.	Alternate method: sitting on side of examining table: direct patient to extend knee	
Upper Leg Hamstrings L5, S1, S2 Knee flexion	Flex your knee. Bring foot towards head	Examiner grasps partially flexed knee about 4 inches above ankle and stabilizes hip with other hand; provides resistance against flexion.)	
Upper Leg Hamstrings L5, S1, S2 Knee flexion	Ask patient to bend knee and keep it bent while you provide resistance.	Alternate methods: have patient sit on edge of examining table with legs dangling. Ask patient to bend knee and keep it bent while you provide resistance or ask patient to squat in a deep knee bend (should be able to flex both knees symmetrically).	
Lower Leg and Ankle Anterior Tibialis L4, 5 Ankle Dorsiflexion	Examiner positions ankle in neutral position and then places other hand on top of foot near fifth metatarsal. Pull your toes toward your nose.	Anchor ankle by stabilizing heel; with your flattened fingers on top of foot, provide resistance to dorsiflexion. Patient attempts to dorsiflex foot against resistance; contraction of tibialis anterior can be seen and palpated Alternate method: ask patient to walk on heels.	

Muscle Group/ Muscle/ Spinal Level	Patient Instructions	Examiner and Observation	Image Dark Arrow = Provider action Light Arrow = Patient action
<p>Lower Leg and Ankle</p> <p>Gastrocnemius S1, 2</p> <p>Plantarflexion of ankle</p>	<p>Press down like on gas pedal.</p>	<p>Anchor ankle by stabilizing heel; with your palm on bottom of foot, provide resistance to plantarflexion. Patient attempts to plantar flex foot at ankle joint against resistance; Contraction of gastrocnemius and associated muscles can be seen and palpated</p> <p>Alternative method: ask patient to walk on toes.</p>	 <p>The diagram shows a lateral view of a right foot and ankle. The examiner's left hand is placed on the heel to stabilize it. The right hand is placed on the bottom of the foot, with a dark arrow pointing downwards, indicating the provider's resistance. A light arrow points upwards from the ball of the foot, indicating the patient's action of plantarflexion.</p>
<p>Ankle and Foot</p> <p>Foot inversion L4, 5</p>	<p>Try to move your foot outward and down.</p>	<p>Position thumb to dorsiflex and invert foot. Patient attempts to raise inner border of foot against resistance; tendon of tibialis posterior can be seen and palpated just behind medial malleolus Try to force foot into plantarflexion and eversion by pushing against head and shaft of first metatarsal; tendon of tibialis posterior can be seen and palpated behind medial malleolus.</p>	 <p>The diagram shows a lateral view of a right foot and ankle. The examiner's left hand is on the heel. The right hand is on the medial side of the foot, with a dark arrow pointing towards the medial malleolus, indicating the provider's resistance. A light arrow points upwards from the medial border of the foot, indicating the patient's inversion action.</p>
<p>Ankle and Foot</p> <p>Foot eversion S1 J</p>	<p>Turn your foot outward.</p>	<p>Secure ankle by stabilizing heel and place your other hand that forces plantarflexion and eversion. Provide resistance to eversion by pushing on fifth metatarsal with palm. Patient attempts to raise outer border of foot against resistance; tendons</p>	 <p>The diagram shows a lateral view of a right foot and ankle. The examiner's left hand is on the heel. The right hand is on the lateral side of the foot, with a dark arrow pointing towards the fifth metatarsal, indicating the provider's resistance. A light arrow points upwards from the lateral border of the foot, indicating the patient's eversion action.</p>

PROCEDURE

Muscle Group/ Muscle/ Spinal Level	Patient Instructions	Examiner and Observation	Image Dark Arrow = Provider action Light Arrow = Patient action
		<p>of peronei longus and brevis can be seen and palpated just above and behind lateral malleolus.</p> <p>Alternative method: patient walks on medial borders of feet.</p>	
<p>Toe</p> <p>Extensor Halucis Longus (EHL) muscle L5</p> <p>Big toe extension</p>	<p>Ask patient to move large toe against resistance up towards their face.</p>	<p>Apply downward resistance on big toe while patients tried to pull toe up towards face. This tests extensor halucis longus muscle.</p>	

k. Deep Tendon Reflexes

Refer to [Reflex Guide](#)

- Encourage patient to relax.
- Position limbs properly and symmetrically. Hold reflex hammer loosely between your thumb and index finger so that it swings freely in an arc within limits set by your palm and other fingers.
- With wrist relaxed, strike tendon briskly using a rapid wrist movement. Reflex response depends partly on the force of your stimulus. Compare response of one side with other.
- Provider will visualize patient to access grade of reflexes based on following scale:

4+= Very brisk, hyperactive with clonus (spasmodic alternation of muscular contraction and relaxation).

3+= Brisker than average; possibly but not necessarily indicative of disease.

2+= Average; normal

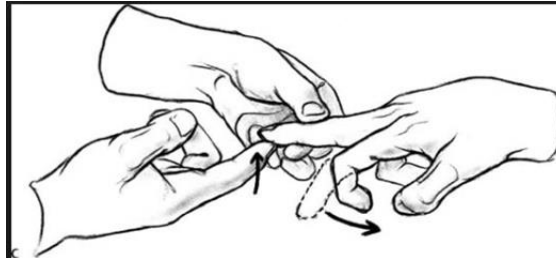1+= Somewhat diminished; low normal

0= No response/ absent.

Radial

Biceps

- Triceps
- Knee
- Ankle
- Hoffmans Sign: Tap or flick the nail of the middle finger to produce flexion of the index finger to the thumb



l. Sensation

- Telepresenter will tickle patient's hands and feet and provider will assess for response to sensation
- Provider will rate sensory function according to following scale:
 - 2: normal
 - 1: present, but diminished (abnormal)
 - 0: absent

m. Neonatal Neurological Exam for NICU follow up appointment

- Hammersmith Neonatal Neurological Examination will be done on children at 6 months old (adjusted age)
 - Refer to [Hammersmith Neonatal Neurological Exam](#) for steps on how to perform exam
 - Provider will score exam

3.4. Post Physical Exam

- a. See [Telehealth Core Presenting Document](#)

3.5. Post Considerations

- a. See [Telehealth Core Presenting Document](#)
- b. Give patient handouts per provider request

4. ADDITIONAL RESOURCES

4.1. References:

- Hickey, J. (2009). The Clinical Practice of Neurological and Neurosurgical Nursing, (6th ed.). Philadelphia, PA: Lippincott Williams & Wilkins. (Chapters 6 and 7). Retrieved from Database Marshfield Clinic Books@Ovid July 2013.
- Jarvis, C. Pocket Companion for Physical Examination & Health Assessment. 6th ed. St. Louis, MO: Elsevier Saunders; 2012.
- Merriam-Webster, Incorporated 2017. <https://www.merriam-webster.com/medical/neurocutaneous>. Accessed July 27,2017
- MedicineNet, Inc. 1996-2017
<http://www.medicinenet.com/script/main/art.asp?articlekey=3850> Accessed July 27,2017
- MedicineNet, Inc. 1996-2017
<http://www.medicinenet.com/script/main/art.asp?articlekey=23457> Accessed July 27,2017
- Farlex, Inc 2003-2017
<http://medical-dictionary.thefreedictionary.com/parachute+reflex> Accessed August 17,2017

4.2. Supporting documents available:

- [Reflex Guide](#)
- [Telehealth Core Presenting Document](#)
- [Hammersmith Neonatal Neurological Exam](#)

PROCEEDURE

5. DOCUMENT HISTORY

Version No.	Revision Description
1.0	New Document
2.0	Administrative Override: Removed Marshfield Clinic Logo, Updated Quick Part in Header, Reformat of Section 2. Updated Scope with MCHS, reformat of section 2. No Content Changes.
3.0	Administrative Override: DCS Checklist.

6. DOCUMENT PROPERTIES

Primary Author: Dvoran, Sharon M

Co-Author(s):

Approver(s): This document has been electronically signed and approved by: Meyer, Christopher L on: 10/18/2017 1:51:58 PM

This document has been electronically signed and approved by: Simon, Tammy A. on: 10/25/2017 3:01:19 PM

This document has been electronically signed and approved by: Krueger, Kori K MD on: 11/1/2017 10:52:34 AM

Live

PROCEDURE